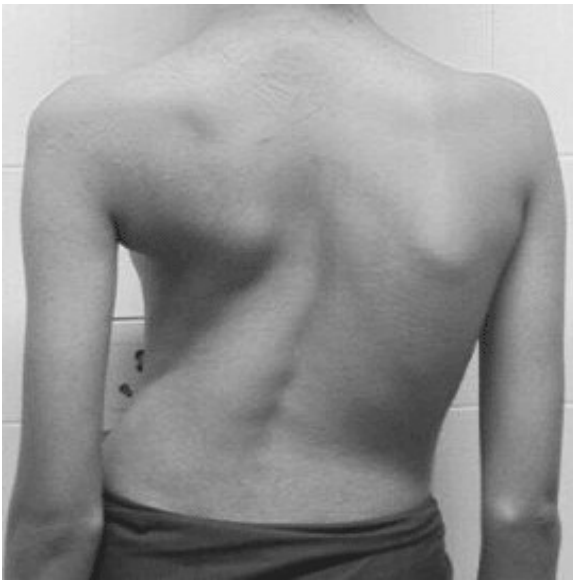
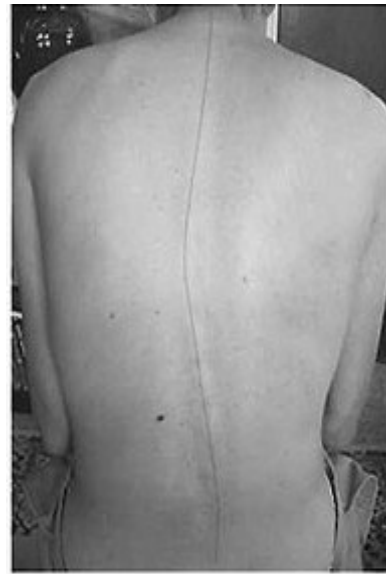
VISCERAL PATTERNS IN SCOLIOSIS

I have found a way of understanding scoliosis patterns that helps me to know how much help my work is going to be in solving these curvatures. There are different degrees of spinal curvatures we see. The more severe patterns, often classified as idiopathic or congenital, have a particular misalignment of the visceral organs that is absent in other spinal curvature patterns. I have found overtime that my Rolfing work (which includes work with the viscera) is never able to reverse, or even come close to correcting, curvatures in persons with this particular visceral misalignment. However my Rolfing work can be very successful with curvatures where this particular visceral pattern is absent. For the sake of clarity in this article I will call the more correctable patterns non-idiopathic scoliosis.



Idiopathic Scoliosis



Non-Idiopathic Scoliosis

There often can be visceral contributors, as well, in these non-idiopathic scoliosis patterns. In this article I will describe a very common visceral pattern involving the kidneys and heart that can contribute to some fairly strong non-idiopathic curvature patterns. There is also a relatively easily corrected pattern of severe lumbar curvature and pelvic torsion that involves the uterus and ovaries. Though, I won't be able to take the space to discuss that here. I just want to be clear that visceral involvement alone does not make the pattern of idiopathic scoliosis difficult to correct. Instead, it seems to be the nature of the visceral restriction in the idiopathic pattern that causes the difficulty.

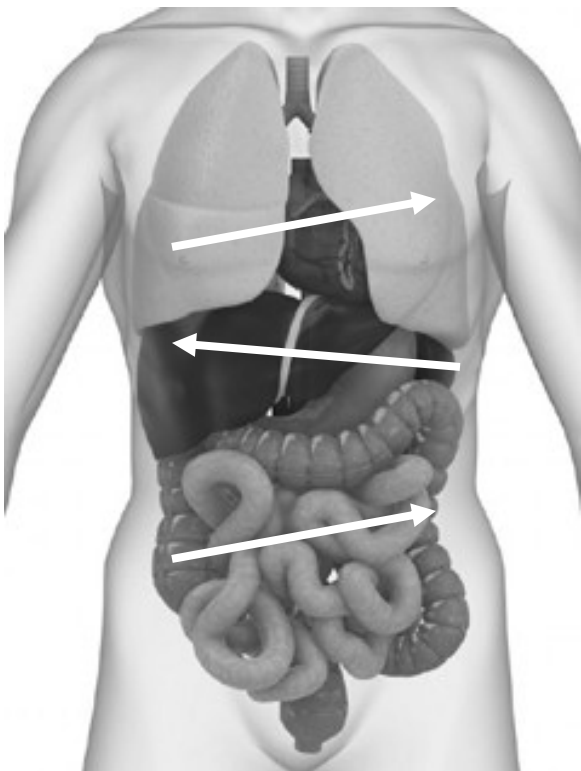
I have found a place in the visceral fascia that is significantly different in persons with idiopathic scoliosis than it is in any other patterns with or without spinal curvatures. This fascial restriction prevents the organs from moving into positions that would allow the rest of the structure to come out of the scoliotic pattern. Additionally this particular visceral misalignment is more recalcitrant than any other visceral misalignment I have ever have found.

Having found this arrangement of the organs again and again and having tried over hundreds of sessions to alleviate the scoliosis in these persons, I have come to the conclusions that 1), my work can only help to keep these idiopathic patterns from becoming destructively severe, and, 2), that I will not be able to correct, reverse or cure these idiopathic patterns with my Rolfing work.

Often persons with severe scoliosis are children or early teens brought to their initial sessions by one or two parents. These families are facing severe decisions about the treatment of a fairly frightful condition. Humanity requires that our predictions be as honest as possible. Having an assessment that tells us the potential for our success is very valuable here. If I find that there is this visceral pattern existing along with the pattern of spinal curvature, then I won't be over promising and under delivering – something that it is never good to do. Because I have this assessment tool, I might also find that the visceral pattern does not exist with the spinal curvature and be able to offer to help quite a bit.

Visceral Misalignment in Idiopathic Scoliosis

This is the visceral pattern I always find with idiopathic scoliosis. From the lower body up: the small intestine, the entire mesocolon and colon are turned and moved toward the left with the small intestine largely distributed on the left lateral and left posterior side of the body; the stomach and liver are strongly misplaced toward the right with the liver rotated posterior on the right side; the kidneys are both shifted rightward and the right kidney is higher than the left; upper most, the heart and lungs are turned toward the left though all are side bent to the right.



The Viscera: arrows indicated the directions

of misalignment the organs take away from usual in idiopathic scoliosis.

Structurally the right side of the pelvis is always in anterior tilt, posterior shift and the left in posterior tilt and anterior shift. The shoulder girdle will be the opposite. The vertebral pattern of idiopathic scoliosis is well documented. (See Aaron and Dahlborn, *Spine*, 1981) The rotations are most extreme at the apex of the lateral excursions. The apex of these excursions are: lateral left at L1 to L2 with left rotation of the vertebrae; lateral to the right at T8 to T9 with right rotation of the vertebrae; and then left toward center at T4 to T5 with left rotation of the vertebrae. The most extreme degrees of rotation are at the T8 to T9 excursion. Neutrality between the curvatures generally occurs at T11, then again above at T3 to T2 and below between L4 and L5. The sacrum and L5 will be side bent to the left with the posterior innominate. This is the pattern of curvature and rotation that are always present with the visceral misalignments I find.

The viscera and the spine normally match in approximately the following ways: The root of the mesentery and center of the mesocolon are between L1 and L2, the site of the apex on the lower left. The central investments of the liver and the stomach are between T8 and T9, the site of the apex to the right. The heart and pericardium are between T4 and T5, the site of upper left apex. There is a direct connection between the rotation of the vertebrae in idiopathic scoliosis and the displacement of the visceral organs most closely associated with those vertebrae. The driver for the spinal rotations may well be in the visceral fascia. This would be more likely than the spine producing the visceral rotations based simply upon the greater preponderance of visceral vs. spinal tissues in the matrix.

I have, as well, had the opportunity to assess a few very young children diagnosed with idiopathic scoliosis, the youngest being 7 months. Though the full severity of the spinal and other structural aspects of scoliosis has yet to emerge, the visceral displacements are present as would be found in a teenager or an adult with severe scoliosis. I speculate that as the organs grow the effects that they have in misaligning the skeleton increase.

Working with Idiopathic Scoliosis

Scoliosis clients often arrive with a physician's diagnosis for the degree of their curvature. The physicians are generally somewhat concerned if the thoracic curvature is between 15 to 25 degrees off vertical. They are more gravely concerned if the curvature is between 25 and 50 degrees.

My work with this type of pattern is to first do a 10-series to free up the fascial matrix in the most thorough and organized way possible. I do pay attention to the asymmetry that dominates the structure, and therefore, always work asymmetrically in my series work. I also work with the viscera relevant to the significant patterns in the torso. I suggest certain asymmetric stretches and exercises. I also suggest they see a cranial Osteopath for intra-cranial and spinal work. I am not against the client wearing a brace to support the work. Though, while receiving this work I wonder if they could be wearing the brace less. As the brace causes much discomfort and is an impediment for teenagers socially, I

don't push bracing either. I primarily encourage the families to thoughtfully examine all of their alternatives.

From this type of series I expect that the client will feel more ease in movement, exhibit some decrease in pelvic torsion and spinal curvature, have less joint pain, be breathing more fully, and in general, to feel better about themselves and be more willing to express embodied presence. When I have been told any follow up measurements, the curvature change from this type of 10-series work is usually 10 to 25 degrees reduction. Generally, the more severe the curvature was initially, the greater is the improvement, with most persons stabilizing between 15 to 25 degrees.

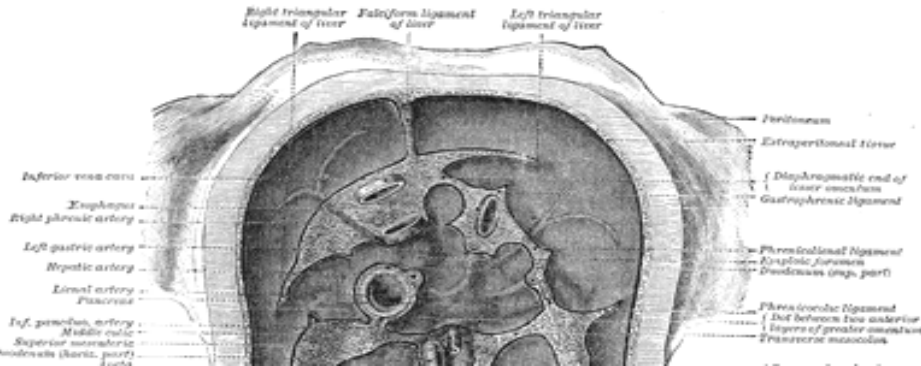
Without continued work and some continuing of the prescribed stretches and exercises, I never see these results last more than a month or two. The degrees of curvature return to their pre-10 series severity and can worsen. Ongoing treatment is required for this not to occur. For ongoing treatment I like to establish a 3-series protocol that has me doing 1), an asymmetric lower session, then 2), an asymmetric upper session and 3), a visceral session. I like to repeat this 3-series three or four times a year. Doing this I have found that the curvatures remain under 30 degrees. There are still significant, obvious curvatures. Given that the entire body is in an asymmetric pattern along with the spinal curvature, there is still significant left to right difference in the pelvis, legs, shoulders and arms. There can be joint pain at any joint with this level of scoliotic pattern.

There are good reasons to do this type of ongoing work. For a young person, keeping the curvatures reduced may lessen the severity of the permanent vertebral damage that occurs with scoliosis. The bones are more susceptible to damage until they harden more in young adulthood. All persons with scoliosis need to be concerned about its effects on the function of various organs. There is significant loss of respiratory capacity and cardiovascular capacity with severe idiopathic scoliosis. Ongoing work seems to bring improvement to respiratory capacity at least. There are also all of the other positive effects of more ease in movement, lessened joint pain and generally feeling better and having a more embodied presence. However, I am not able to endorse expectations of anything near complete reversal even with dedicated ongoing work.

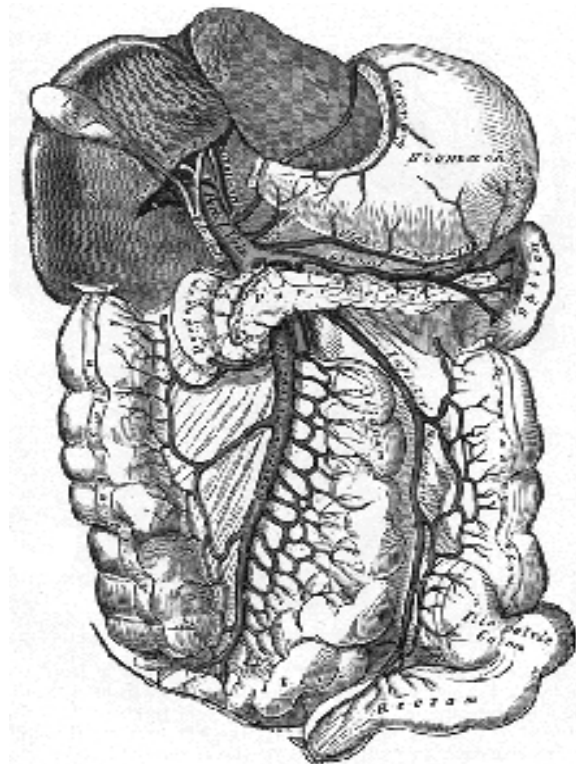
The Tissue that Won't Change

I can suggest a reason why these patterns are not reversing with my Rolfing work. There seems to be a striking difference between this idiopathic scoliosis pattern and other types of curvatures in one area of the fascial matrix. This difference is in the region of the posterior diaphragm, slightly right of the midline. There is a lack of adaptability in this area. The tissue is restrained in a way that indicates something has shortened and pulled the organs and the diaphragm tightly together and toward the right. The structures which are in this area are: 1), the fascia of the diaphragm near the falciform ligament and vena cava foramen; 2), the diaphragmatic portion of the falciform ligament; 3), the portal vein that carries the blood from the intestines to the liver; 4), the right triangular ligament of the liver which is on the posterior diaphragm; and 5), the vena cava itself which crosses through the diaphragm near to the falciform ligament. Any or all of these structures

might be shortened or uniquely configured in some way to produce the restraint in this area.



Posterior diaphragm showing foramen of the vena cava, right triangular ligament of the liver and diaphragmatic portion of the falciform ligament



Liver held up to show the portal vein that connects the mesentery and mesocolon to the liver. Falciform ligament would be in the division between the two lobes medial to the portal vein.

I don't now for certain which, if any, of these tissues is involved in the visceral restraint here. What I do know is that my attempts to correct the position of the organs mis-

arranged in these persons becomes less successful as I near this area of the posterior diaphragm, just right of the midline. My visceral work has greater temporary effects on the lungs, small intestine and large intestine than it does on the liver, stomach, heart and kidneys. In addition, using indirect methods of assessment (once any overlying incidental restrictions are released) the strain patterns in the liver, stomach heart and kidneys all lead to this place in the fascial matrix. Even my extrinsic work has its least effects here, which would be around the T8-T9 region of the spine.

Experiencing the same restriction, in just this particular place, with all of my patients with the idiopathic pattern over the years is what has led me to assume there might be some unique formation of the visceral fascia here. I hope that some day someone with more medical knowledge and access to the medical establishment will investigate this. Perhaps it could be that someday there will be a delicate pediatric surgery that can correct what ever unique formation is driving this visceral misalignment.

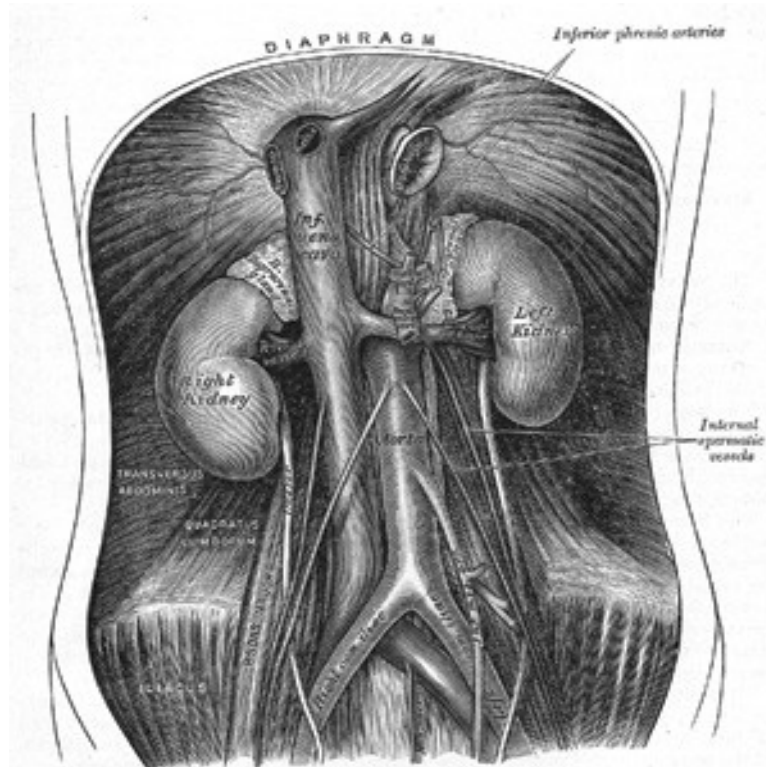
Visceral Misalignment in Non-Idiopathic Scoliosis

There are many, many other clients I have seen who have spinal curvatures, some of them very strong and noticeable, that do not have idiopathic scoliosis with the accompanied visceral misalignment. Some of these persons have been told they have scoliosis by a physician or chiropractor, etc. They may have a lot of pelvic and whole body asymmetry, some even with right innominate anterior tilt and left posterior tilt as with idiopathic scoliosis. They might also have the apex of their curvatures at L1-L2 and T8-T9. What I have found is that, if the visceral alignment I described above is not present, then, this is a scoliosis or spinal curvature pattern I can correct with my Rolfing work.

My 10-series work with these clients would proceed as described above with the idiopathic scoliosis client. I would do an asymmetrically applied series, paying attention to visceral irregularities as I went. Just as with any client, if the curvature and asymmetry patterns are strongly held (which can happen for numerous reasons) correction may take more than ten sessions.

The most common visceral driver of spinal curvature patterns in non-idiopathic scoliosis clients that I have seen is a misalignment of the kidneys that effects the position of the heart and major arteries and veins of the circulatory system. (The most common non-visceral driver of spinal curvatures I have seen is asymmetric girdles created by some severe injury or repetitive use pattern in the appendicular structure.) It is common for kidneys being affected by some disease or even whiplash to become misplaced. Kidneys structurally can slip inferior along a path medial to the ascending and descending branches of the colon. The kidneys are retroperitoneal, that is, they are behind the posterior abdominal bag. The only attachments to the body that they have are to the circulatory system and to the ureters that run between them and the bladder.

The circulatory attachments provide all of the positional stability for the kidneys. The kidneys are attached to one another by the renal artery and vein. Via the renals, they are attached inferiorly to the abdominal aorta and vena cava and then to the femoral arteries and veins. Superiorly, via the renals, they are attached to the vena cava and aorta and then to the heart itself.



Kidneys with attachments, via the renal artery and vein, to the aorta and vena cava. These divide below into the femoral arteries and veins. Above the diaphragm the aorta and vena cava attach to the heart.

Any strong whiplash with a vector through the kidneys can drive a kidney superior or inferior. A kidney will also respond by moving inferior to any restrictions or damage to the ureter attached to it. This damage can be caused by bacterial infection or physical damage from whiplash or manipulation. The ureters run across the front face of the psoas muscles and can be pulled on or impinged by improper psoas work that drags along or across the face of the psoas. In addition, any illness in a kidney can diminish its function and the other kidney, being the one most used, will grow in size while the damaged kidney shrinks. This imbalance can cause the larger kidney to move inferior, with the smaller moving more superior.

When a kidney moves inferior it is called ptosis. With one sided ptosis, I most often find that the other kidney is positioned a little higher than normal. It is as if there is a required repositioning of the opposing kidney. I speculate that this is due to the structural and functional demands of the renal artery and vein. (There can be bilateral ptosis but this does not tend to drive spinal curvature.) What I always find with a unilateral ptosed

kidney is the heart and lungs pulled into a side bend toward the side of the ptosis. I also always find a corresponding side bend in the region of T4 through T8 to the same side with a rotation to the opposite side. This can look very much like the thorax of idiopathic scoliosis particularly if it is the right kidney in ptosis. Note: the right kidney is found superior in idiopathic scoliosis.

Unilateral kidney ptosis is also accompanied by pelvic asymmetry, with the side of the ptosis being in anterior tilt and, most often, posterior shift. (The presence of anterior shift with this anterior tilt would be driven by other factors than the kidney pattern). There is also always a good deal of patella diversion, i.e., counter-rotation between the tibia and fibula, on the same side of the ptosis. The femur will be medially rotated and the tibia will be lateral. (There could be an exception if there are other factors driving a femur rotated lateral out of pattern with the anteriorly tilted innominate.)

Full correction of the spinal curvatures, pelvic asymmetry and knee misalignment will require that the kidneys be repositioned. If the pattern has been in the body for more than a few months, along with getting both kidneys repositioned, the visceral work will also need to address the strain patterns in the renal, portal and bilateral femoral arteries and veins, as well as, the pericardium, heart and superior branches of the circulatory system. I must note that it is never advisable to address issues in only one kidney. If you are going to reposition one, you will need to reposition the other. Repositioning the kidneys, repairing ureters, and realigning the arteries, veins and heart of the circulatory system, requires knowledge of indirect visceral manipulation techniques. There have been some early techniques of direct repositioning of kidneys that I don't recommend. If there is any ureter strain, these direct attempts at repositioning can exacerbate the problems with the ureter, and, probably, the kidney will not stay repositioned.

Because of the strong effects that the viscera can have on structural alignment, there are always opportunities for segments of the spine to rotate or side bend in response to visceral strain. I believe the pattern with the mis-arranged kidneys and circulatory system is the one most common with whole spine curvature patterns that include with pelvic and shoulder girdle asymmetries.

Other Visceral Issues

I will take this opportunity to address another visceral issue in regards to the work of Structural Integration. I wrote an article several years ago, "Including the Viscera in the Work of Rolfing," Rolf Lines 1997, that presented a case of visceral contribution to kyphosis. In that article I wrote about how and why the viscera effects structural alignment. I wrote again about this in an article, "Including the Viscera in Structural Work," IASI, 2003 Yearbook of Structural Integration. I won't go into this material again here. You can write to me if you want a copy of these articles.

What I want to address is a more basic question: When we do visceral work are we doing Structural Integration? This is often asked because the techniques for visceral work are

primarily indirect and involve assessments and treatments that are similar to those used in cranial work.

My favorite answer to questions about whether something is or is not S.I. work is one that I heard Bill Smythe give about his trauma work. What he said essentially was, if it creates more structural integration, then it is Structural Integration. I think this is true for visceral work, as well.

Another reason why visceral work belongs in the practice of S.I. is that the strain patterns that fix, inhibit and misalign the visceral organs are held in the connective tissue matrix. Visceral techniques, be they ever so indirect, are still effecting changes in the connective tissue matrix to create their positive results. The connective tissue associated with the viscera is high elastin tissue. That is, the ratio of elastin to collagen fibers in this tissue is very high on the elastin side of things. With this sort of tissue, indirect techniques seem to work better. Whether it is mechanical reflex or chemical bonding, with high elastin tissues it seems to be necessary to take the tissue into its strain pattern and wait for a release rather than attempt to directly push or pull a restriction apart. So, the indirect technique is just another manipulation technique in the Structural Integrator's repertoire for use in releasing, sculpting and transforming the connective tissue matrix.

I hope you have enjoyed this discussion of a small aspect of our work. I welcome your comments and questions at any time.

This article was originally published in the 2008 Yearbook of the International Association of Structural Integrators.